CLINICAL CHARACTERISTICS, TREATMENT, AND SURVIVAL OUTCOME OF CHILDHOOD ATYPICAL TERATOID/RHABDOID TUMORS (ATRT): A RETROSPECTIVE 20-YEAR FOLLOW-UP STUDY

Jéssica Benigno Rodrigues[1], Andrea Maria Cappellano[1], Frederico Adolfo Benevides Silva[2], Patricia Alessandra Dastoli[4], Maria Teresa de Seixas Alves[3], Nasjla Saba da Silva[1]
[1]Instituto de Oncologia Pediátrica - IOP/GRAACC/UNIFESP, Department of Pediatric Neuro-oncology, São Paulo, Brazil, [2]Instituto de Oncologia Pediátrica/IOP/GRAACC/UNIFESP, Department of Radiology, Brazil
[3]Universidade Federal de São Paulo – UNIFESP, Department of Pathology, [4]Instituto de Oncologia Pediátrica/IOP/GRAACC/UNIFESP, Department of Neurosurgery, Brazil

Background: ATRT is a rare and aggressive central nervous system that which prognosis has improved over the years due to multimodal therapy, including radiotherapy. We wanted to evaluate clinical features, therapeutic approaches, and outcome in children with ATRT in a single institution.

Methods: We retrospectively collected clinical information on 28 pediatric patients with ATRTs treated from 2000 to 2020 and analyzed the data for this series. Survival analyses were performed using the Kaplan-Meier method.

Results: The median age at diagnosis was 2.3 years (0-14 years), and male/female ratio was 1:15. Vomiting was the most common symptom at diagnosis (59%). Intracranial hypertension was present in 58.6%.

The tumor's localization was supratentorial in 11 patients (39.3%), infratentorial in 16 patients (57.1%) and spinal cord in one patient (3.6%).

Figure 1
Tumor Location Distribution

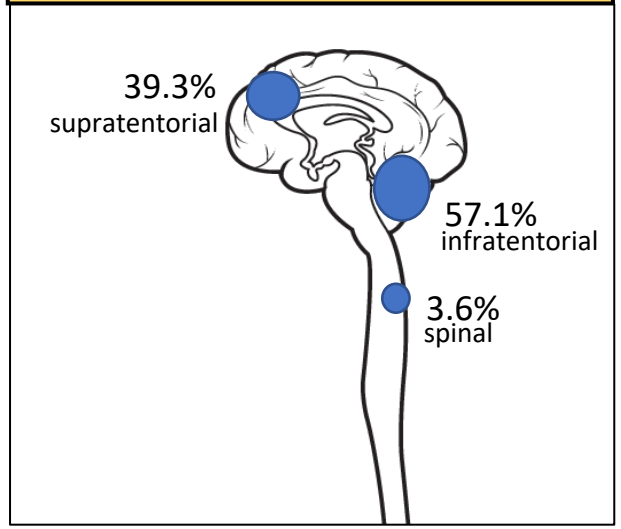

Gross total resection of the primary tumor was achieved in 50% of patients. The treatment was based on age and staging .

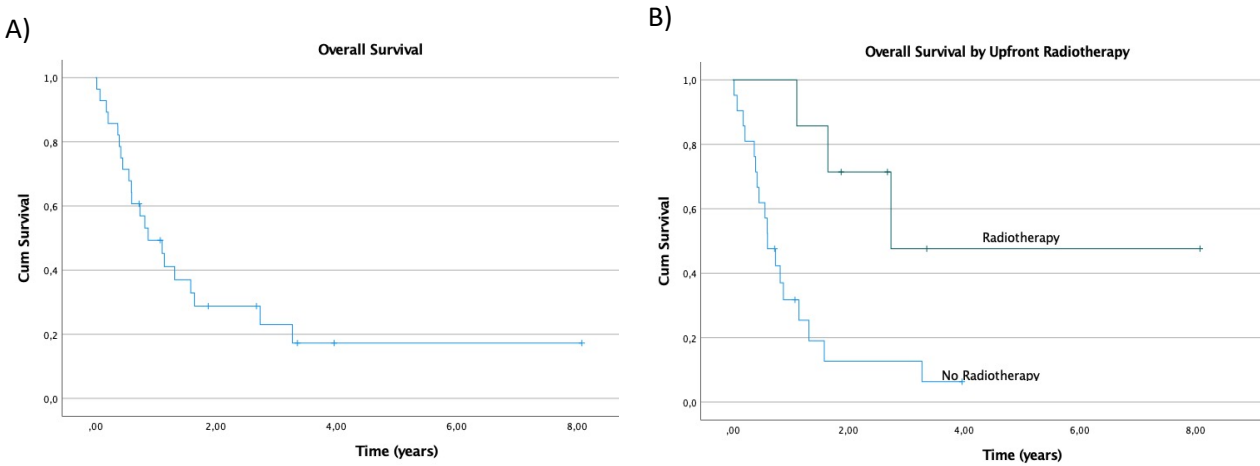

Figure 2. Kaplan-Meier survival curves for A) Overall Survival B) Survival by Upfront Radiotherapy

Twenty-three patients under three years had the intention to perform HDCT followed by ASCT, however progressive disease (PD) was observed in seven patients and other four died of sepsis before completing all cycles of chemotherapy. In 11/23 patients the procedure was completed, five of them are still alive. Five patients were ≥ 3-year-old, two of them died due to PD and the other two are alive. The 1 and 5-year event-free survival (EFS) were 40.1%, 9.3% and overall survival (OS) 49.3%, 17.3%, respectively. In the group that received ASCT the 5y-EFS and OS were 15.2% (p=0.012) and 30.3% (p=0.009), respectively. Patients who received upfront RT had a 5y-OS of 47.6%, while no children who did not received RT in first treatment was alive five years after diagnosis. Relapse/progression occurred in 17 patients of all patients and just one patient is alive.. **Conclusion:** HDCT followed by ASCT did not improve EFS and OS in our analysis whereas upfront radiotherapy seems to improve survival rates.

GRAACC
Hospital IOP Instituto de Oncologia Pediátrica
Parceria técnico-científica UNIFESP Universidade Federal de São Paulo